



Published in final edited form as:

Ophthalmology. 2017 November ; 124(11): 1678–1689. doi:10.1016/j.ophtha.2017.05.012.

Update on the Management of Infectious Keratitis

Ariana Austin, MS¹, Tom Lietman, MD¹, and Jennifer Rose-Nussbaumer, MD^{1,2}

¹Francis I. Proctor Foundation, University of California, San Francisco

²Department of Ophthalmology, University of California, San Francisco

Abstract

Infectious keratitis is a major global cause of visual impairment and blindness, often affecting marginalized populations. Proper diagnosis of the causative organism is critical, and while culture remains the prevailing diagnostic tool, newer techniques such as *in vivo* confocal microscopy are helpful for diagnosing fungal keratitis and *Acanthamoeba*. Next generation sequencing holds the potential for early and accurate diagnosis even for organisms that are difficult to culture by conventional methods.

Topical antibiotics remain the best treatment for bacterial keratitis, and a recent review found all commonly prescribed topical antibiotics to be equally effective. However outcomes remain poor secondary to corneal melting, scarring and perforation. Adjuvant therapies aimed at reducing the immune response responsible for much of the morbidity associated with keratitis include topical corticosteroids. The large, randomized controlled Steroids for Corneal Ulcers trial found that while steroids provided no significant improvement overall, they did appear beneficial for ulcers that were central, deep or large, non-*Nocardia* or classically invasive *P. aeruginosa*, patients with low baseline vision, and when started early after the initiation of antibiotics.

Fungal ulcers often have worse clinical outcomes than bacterial ulcers, with no new treatments since the 1960's when topical natamycin was introduced. The randomized controlled Mycotic Ulcer Treatment Trial showed a benefit of topical natamycin over topical voriconazole for fungal keratitis, particularly among those caused by *Fusarium*. The second Mycotic Ulcer Treatment Trial showed that oral voriconazole did not improve outcomes overall although there may have been some effect among *Fusarium* ulcers. Given an increase in non-serious adverse events the authors concluded that they could not recommend oral voriconazole at this time.

Viral keratitis differs from bacterial and fungal cases in that is often recurrent and is common in developed countries. The first Herpetic Eye Disease Study (HEDS) showed a significant benefit of topical corticosteroids and oral acyclovir for stromal keratitis. HEDS II showed that oral acyclovir decreased the recurrence of any type of HSV keratitis by approximately half.

Corresponding Author: Jennifer Rose-Nussbaumer, MD, Assistant Professor, UCSF/Proctor Foundation, 513 Parnassus Ave, S334H, San Francisco, CA 94122, (415) 502-2666.

Publisher's Disclaimer: This is a PDF file of an unedited manuscript that has been accepted for publication. As a service to our customers we are providing this early version of the manuscript. The manuscript will undergo copyediting, typesetting, and review of the resulting proof before it is published in its final citable form. Please note that during the production process errors may be discovered which could affect the content, and all legal disclaimers that apply to the journal pertain.

Future strategies to reduce the morbidity associated with infectious keratitis are likely to be multidimensional with adjuvant therapies aimed at modifying the immune response to infection holding the greatest potential to improve clinical outcomes.

INTRODUCTION

Corneal disease remains the leading cause of monocular blindness worldwide, especially affecting marginalized populations.¹ Corneal opacities, which are largely caused by infectious keratitis, are the fourth leading cause of blindness globally and are responsible for 10% of avoidable visual impairment in the world's least developed countries.^{2,3} Approximately 2 million people develop a corneal ulcer every year in India alone.^{4,5} In the United States infectious keratitis is often associated with contact lens wear,^{6–8} but in developing countries it is more commonly caused by ocular trauma sustained during agricultural work.^{9–12} In this review we explore the current literature and future directions of the diagnosis and treatment of infectious keratitis.

DIAGNOSTICS

Proper diagnosis of keratitis is essential to determining treatment and achieving resolution of infection. The mainstay in diagnosis is still Gram stain and culture of corneal samples despite imperfect sensitivity.^{13–15} Gram and Giemsa stains are advantageous because they provide instant results, with Gram stain accurately detecting causative organism 60–75% of the time for bacterial cases and 35–90% in fungal cases. Giemsa has a sensitivity of 40–85% for diagnosing fungal cases.^{16–18} Blood and chocolate agar are most commonly used to culture bacteria, while Sabouraud's agar or potato dextrose are best for isolating fungus, and non-nutrient agar with *Escherichia Coli* overlay can be used to culture *Acanthamoeba*. Thioglycollate broth is another option to identify aerobic or facultatively anaerobic bacteria, but contaminant is a problem and often it is difficult to determine if isolated organisms are the etiology of infection.¹⁹ Viral keratitis is diagnosed largely on clinical exam because of its characteristic dendritic appearance,²⁰ but PCR is sometimes used to confirm diagnosis because of its high sensitivity.²¹

There is still substantial room for exploration of novel methods of diagnosing infectious keratitis. *In vivo* confocal microscopy (IVCM) has grown in popularity in recent years due to its rapidity and high sensitivity in detecting larger organisms such as filamentous fungus, acanthamoeba, and *Nocardia* bacteria [Image 1].^{22–26} Anterior segment optical coherence tomography (AS-OCT) has been used more recently to provide an objective measure of corneal infiltrate and/or scar size or to monitor corneal thinning during treatment.^{27,28}

BACTERIAL KERATITIS

In the United States bacterial keratitis is most associated with contact lens use.¹⁹ Severe cases can progress rapidly, and can cause permanent vision loss requiring corneal transplantation.

Antibiotics

Topical antibiotics remain the first-line treatment for bacterial keratitis. Clinicians weigh many factors when choosing an antibiotic regimen, including, broad-spectrum coverage, toxicity, availability and cost, and region-specific epidemiology of pathogens and resistance patterns. Indeed, a recent international survey of cornea specialists found that concerns over several of these factors were predictive of antibiotic choice.²⁹

A recent Cochrane-style review of high quality, randomized, controlled, clinical trials on the management of bacterial keratitis with topical antibiotics identified 16 trials comparing 2 or more topical antibiotics over at least 7 days. The authors found no significant difference in the relative risk of treatment success defined as complete re-epithelialization of the cornea or on time to cure.³⁰ While there was an increase in the relative risk of minor adverse events such as ocular discomfort or chemical conjunctivitis with aminoglycoside-cephalosporin compared with fluoroquinolones, there was no difference in serious complications.^{30–33,34}

Although bacterial ulcers are usually responsive to treatment with available topical antibiotic drops, an increase in the rates of antibiotic resistant infections such as methicillin resistant *Staphylococcus aureus* (MRSA) in North America has caused concern. The United States Center for Disease Control (CDC) estimates that 2 million people are infected with drug resistant microbes each year.³⁵ Approximately 80% of ocular isolates of MRSA in the US have been reported to be resistant to the most commonly prescribed antibiotic class, the fluoroquinolones.^{36–38} In the Steroids for Corneal Ulcer Trial (SCUT), *in-vitro* susceptibility was correlated with clinical outcomes.^{39,40,41} Therefore, corneal culture and sensitivity testing is recommended for all corneal ulcers. Assessing response to treatment is critical and if the patient appears to be worsening on treatment one can consider switching to fortified broad-spectrum antibiotics if the initial therapy was fluoroquinolone monotherapy. On the other hand, if initial therapy was with a broad-spectrum fortified antibiotic, toxicity from the drops can become the most important factor impacting healing and reducing therapy is often advised.

Even when bacterial ulcer pathogens are susceptible to available topical antibiotics, clinical outcomes can be poor secondary to irregular astigmatism and corneal opacity. Therefore investigating factors that mitigate the inflammatory response to infection which results in corneal melting and subsequent scarring may be the way to have the greatest impact on clinical outcomes in bacterial keratitis.

Anti-collagenases

During acute infection fibroblasts, keratocytes and other inflammatory cells secrete enzymes such as collagenases and matrix metalloproteinases (MMPs) that are involved in protein degradation and keratolysis. Directing therapy toward stabilization of corneal melting may reduce the incidence of severe complications of infectious keratitis such as corneal perforation and the need for therapeutic penetrating keratoplasty. Tetracyclines have been shown to inhibit collagenase and have demonstrated antimetalloproteinase activity *in vitro*.^{42–44} In one laboratory study, alkali-induced corneal ulceration in rabbits was dramatically reduced from 85% to 9% in those randomized to high dose systemic

tetracycline administration.⁴⁵ In another rabbit study, systemic doxycycline reduced the rate of corneal perforation in pseudomonas ulcers by approximately 50%.⁴⁶ Unfortunately there are no high quality randomized controlled trials in humans to guide clinicians in the use of adjuvant doxycycline for the treatment of corneal ulceration despite its widespread use among corneal specialists.

Steroids

The use of adjuvant corticosteroids has long been debated in the treatment of bacterial keratitis.^{47–49} Proponents of the use of corticosteroids argue that they improve outcomes by reducing inflammation, thereby reducing scarring, neovascularization, and stromal melt.^{49–52} However, others argue that corticosteroids delay epithelial healing and may even worsen infection.^{53–56}

A recent Cochrane review of adjuvant topical steroids for bacterial keratitis identified four randomized controlled trials comparing adjuvant steroids to topical antibiotics alone.⁵⁷ Three small randomized controlled trials examining the benefit of adjuvant topical steroids for the treatment of corneal ulcers found no difference in visual acuity outcomes or healing times between those randomized to topical antibiotic alone versus topical antibiotic plus topical steroid.^{58–60} The fourth and largest randomized controlled trial to investigate the role of steroids in the treatment of bacterial ulcers to date was the Steroids for Corneal Ulcers Trial (SCUT). SCUT was a randomized, double-masked, placebo-controlled clinical trial that compared adjunctive topical corticosteroids to placebo in the treatment of bacterial corneal ulcers.⁶¹ Five hundred study participants with culture-positive bacterial ulcers were enrolled at Aravind Eye Hospitals in Madurai, Coimbatore, and Tirunelveli, India, the University of California, San Francisco, and at the Dartmouth-Hitchcock Medical Center in New Hampshire. Patients were randomized to receive either topical prednisolone sodium phosphate 1.0% or topical placebo starting after a 48-hour course of topical moxifloxacin 0.5%.

Despite the overall data showing no difference in outcomes such as 3-month visual acuity, 3-month scar size or rate of perforation between the corticosteroid and placebo groups, subgroup analyses suggested that corticosteroids are beneficial in certain subgroups. Patients with low vision (counting fingers or worse) at baseline had 1.7 lines better vision at 3 months in the corticosteroid group compared to the placebo group ($P=0.03$). Central ulcers, covering the central 4-mm pupil, that were treated with corticosteroids also had better 3-month BSCVA compared with placebo (approximately 2 lines better; $P=0.02$). Similarly patients with deep ulcers at baseline fared better with topical steroids (1.5 lines better; $P=0.07$). Timing of steroid administration also proved to be a significant factor, with patients randomized to corticosteroids after only 2–3 days of antibiotics having better BSCVA at 3 months than those randomized to placebo (approximately 1 line better BSCVA; $P=0.01$).⁶²

Evidence from SCUT subgroup analyses also revealed organism subtype to be an important factor to consider when initiating adjuvant topical steroids in bacterial ulcers. *Nocardia*, a partially acid-fast atypical bacteria, represented 10% of all ulcers in SCUT. *Nocardia* ulcers randomized to corticosteroids had 0.40 mm larger infiltrate or scar size at 3 months compared with placebo ($P=0.03$), although this did not result in worse 3-month BSCVA

($P=0.21$) [Figure 1].⁶³ This trend continued at 12 months, with non-*Nocardia* ulcers faring better with corticosteroids (1 line improvement of BSCVA; $P=0.02$) and *Nocardia* ulcers faring worse (average scar size increased by 0.47mm; $P=0.02$; no difference in BSCVA).⁶⁴ Overall, *Pseudomonas aeruginosa* ulcers did not benefit from the addition of corticosteroids, however the classically invasive subtype of *P. aeruginosa* demonstrated 2.5 lines of visual acuity improvement at 3-month BSCVA when randomized to steroids versus placebo [Figure 2].⁶⁵

The authors of the Cochrane review concluded that there was not enough evidence to support the use of adjuvant steroids, given that of the four trials reviewed only SCUT was sufficiently powered.⁵⁷ Given the findings of these subgroup analyses it is our practice to administer adjuvant topical steroids in culture positive non-*Nocardia* bacterial keratitis starting 48 hours after the administration of appropriate topical antibiotics. Confirmation of the findings of the SCUT subgroup analysis is required with a well-designed randomized controlled clinical trial.

FUNGAL KERATITIS

Fungal ulcers often have worse outcomes than bacterial ulcers, and there is little evidence to guide treatment.⁶⁶ Fungal keratitis represents a relatively small percentage of infectious keratitis cases in regions with temperate climates, however in tropical climates it can cause up to 50% of infectious ulcers.^{66–68} Contact lens wear has been identified as a risk factor for fungal keratitis in the United States and an outbreak of *Fusarium* keratitis among contact lens wearers was related to the ReNu Moistureloc contact lens solution.^{69–72} There have been no new FDA approved treatments since natamycin, a topical polyene, was introduced in the 1960's.

Topical Treatments

Effective treatment with topical natamycin 5% is limited by its poor penetration into the corneal stroma.⁷³ Topical amphotericin B 0.3% to 0.5% is an alternative, but its use requires access to a compounding pharmacy and is limited by toxicity. Voriconazole, a newer generation triazole, has gained popularity in the treatment of fungal keratitis due to its excellent ocular penetration.⁷⁴ In addition, in one *in vitro* study, voriconazole was the only drug tested in which 100% of fungal isolates commonly implicated in keratitis were susceptible.⁷⁵

The first Mycotic Ulcer Treatment Trial (MUTT I) was a double-masked, randomized controlled clinical trial that compared topical natamycin and topical voriconazole in the treatment of filamentous fungal ulcers.⁷⁶ Smear-positive moderate fungal ulcers were enrolled and randomized to receive either 1% topical voriconazole or 5% topical natamycin. After enrollment of 323 patients, the Data Safety and Monitoring Committee (DSMC) recommended stopping the trial because those randomized to topical voriconazole had a statistically significant increase in the rate of corneal perforation and/or therapeutic penetrating keratoplasty (TPK) than those randomized to natamycin ($P=0.009$).⁷⁶ Those randomized to topical natamycin also had on average 1.8 lines better BSCVA at 3 months compared to the voriconazole group ($P=0.006$).⁷⁶ This difference was particularly notable

among *Fusarium* ulcers which had 4-lines better BSCVA if randomized to natamycin instead of voriconazole ($P<0.001$)[Figure 3].⁷⁶ Three-month scar size was smaller for *Fusarium* ulcers treated with natamycin than those treated with voriconazole (coef = -1.02 mm; $P<0.001$), but not for non-*Fusarium* ulcers (coef = -0.17 mm; $P=0.42$).⁷⁶ However, a higher percentage of patients were culture positive for fungus on day 6 of treatment in the voriconazole group than in the natamycin group regardless of the organism suggesting that voriconazole is inferior to natamycin in the treatment of all fungi ($P<0.001$).⁷⁶

The results of MUTT I show a benefit of natamycin over voriconazole for topical treatment of fungal keratitis, and in particular for *Fusarium* keratitis. These results have been confirmed by a second randomized clinical trial⁷⁷ and a recent Cochrane review.⁷⁸

Oral Voriconazole

Although topical voriconazole failed to show improved outcomes compared with natamycin, there are several reasons that oral voriconazole may have efficacy in the treatment of fungal keratitis. First, intermittent dosing of topical medications may result in intervals of sub-therapeutic drug levels and oral medications may provide more steady-state drug levels at the site of infection. One study comparing aqueous samples after topical and oral voriconazole found that topical administration of voriconazole resulted in highly variable aqueous concentrations with troughs well below the MIC90 for most fungi while oral voriconazole provided therapeutic drug level that remained relatively constant.⁷⁹ Of note, in many case reports of successful treatment with topical voriconazole, oral and/or intravenous voriconazole was used in conjunction with the topical medication.^{80,81}

The Mycotic Ulcer Treatment Trial II (MUTT II) was a double-masked, randomized, placebo-controlled clinical trial investigating the effect of adjuvant oral voriconazole versus oral placebo for smear positive filamentous fungal keratitis.⁸² There was no difference in the primary outcome, rate of perforation and/or need for TPK, between the two arms at 3 months (HR 0.82; $P=0.29$).⁸² There was also no difference in secondary outcomes such as visual acuity ($P=0.77$), scar size ($P=0.35$), rate of re-epithelialization ($P=0.65$). There were significantly more adverse events in the oral voriconazole group including elevations in aspartate aminotransferase or alanine aminotransferase ($P=0.003$) and visual disturbances ($P=0.03$) than patients in the placebo group.⁸²

A subsequent subgroup analysis did find a possible benefit to oral voriconazole in *Fusarium* ulcers.⁸² Other potential adjuvant treatments for fungal keratitis include intracameral injection of amphotericin with or without hypopyon drainage^{83-86,87} or intrastromal injection of voriconazole.⁸⁸⁻⁹⁰ However, more study of these techniques with well-designed randomized controlled trials is necessary to determine their benefit. Therefore, at this time, topical natamycin remains the most evidence-based treatment for filamentous fungal keratitis and oral voriconazole should be considered if the organism is *Fusarium*.

VIRAL KERATITIS

Herpes simplex virus (HSV) keratitis affects an estimated 500,000 people in the United States and an estimated 1.5 million globally.⁹¹ It is the most common cause of unilateral

infectious corneal blindness in much of the developed world.⁹² Viral keratitis differs from bacterial and fungal keratitis in that it can become chronic and recurrent. Besides being a painful, sight-threatening infection, HSV keratitis has been shown to significantly impact quality of life even when patients are not experiencing an active infection.⁹³ Less common forms of viral keratitis include varicella-zoster virus (VZV) keratitis, and cytomegalovirus (CMV) keratitis.

Topical Treatments

Topical treatments for viral keratitis include antiviral medications and adjuvant topical corticosteroids. The topical antiviral trifluridine is the most commonly prescribed topical antiviral medication for HSV keratitis in the United States.⁹⁴ While it is effective in treating HSV keratitis, it has low bioavailability and causes ocular surface toxicity, so its use has become more limited as newer topical antivirals are developed.⁹⁵ Topical acyclovir is the first line treatment for HSV keratitis in Europe as it has been shown to be just as effective as trifluridine with less ocular surface toxicity. Unfortunately, it is unavailable in the United States. Ganciclovir is a newer synthetic medication with more broad-spectrum antiviral coverage. In addition to treating HSV and VZV keratitis, topical ganciclovir is also effective in treating keratitis caused by CMV.⁹⁶ Ganciclovir has been shown to be just as effective as acyclovir, while causing less ocular toxicity. It may also be less likely to promote drug resistance.^{96,97} Northwestern University is currently conducting a large randomized controlled trial investigating ganciclovir for the treatment of VZV keratitis (NCT02382588).

Topical corticosteroids are also sometimes used as adjuvant therapy to topical antivirals. The Herpetic Eye Disease Study I (HEDS I) evaluated the effectiveness of corticosteroids in treating HSV stromal keratitis. In this randomized controlled trial 106 patients with active HSV stromal keratitis were randomized to receive either topical prednisolone phosphate or placebo, tapered over a 10 week period. All patients received topical trifluridine. HEDS I found that the median time to treatment failure was drastically shorter in the placebo group: 17 days in the placebo group and 98 days in the topical steroids group ($P<0.001$).⁹⁸ Time to resolution of infection was significantly shorter in the group receiving topical corticosteroids, with a median of 26 days for those taking corticosteroids and 72 days for those taking placebo ($P<0.001$). Visual acuity at 6 months was similar across groups.

Oral Treatments

The HEDS I trial also investigated adjuvant oral acyclovir as a treatment for HSV stromal keratitis. One hundred and four patients receiving both topical trifluridine and corticosteroids were randomized to receive 200mg oral acyclovir or placebo, to be taken 5 times daily for 10 weeks.⁹⁹ Although the investigators found that oral acyclovir delayed treatment failure (from 62 days in the placebo group to 84 days in the acyclovir group), this result was not statistically significant ($P=0.46$). Oral acyclovir did result in a statistically significant improvement in BSCVA at 6 months ($P=0.04$) but the importance of this result is hard to determine given that there was a relatively large difference in baseline BSCVA between groups. Oral acyclovir has also been shown to be efficacious against VZV keratitis and the results of HEDS I are often applied similarly to its treatment.

Valacyclovir, a newer antiviral, is well tolerated and there is some evidence that it may have better ocular penetration.^{100,101} Additionally, the treatment dose for valacyclovir is 1g three times daily, as opposed to acyclovir which is 400mg five times daily (800mg five times daily for VZV), which aids in patient compliance. Oral valganciclovir is the preferred treatment for CMV stromal keratitis, but it has significant side effects, including aplastic anemia, which must be closely monitored.¹⁰²

In our practice we generally use oral antivirals to avoid ocular toxicity that can complicate topical therapy and obscure the clinical picture. We reserve topical medications for adjuvant treatment when oral medications are not adequate or in patients who are not good candidates for systemic therapy.

Prophylaxis

HEDS II examined the prolonged use of oral acyclovir for recurrent ocular HSV. This large, multi-center, randomized, placebo-controlled trial, found that ocular HSV recurrence was 45% lower in the acyclovir group, with 19% in the acyclovir group experiencing recurrence and 32% in the placebo group experiencing recurrence by 12 months ($P<0.001$).¹⁰³

Herpes zoster ophthalmicus (HZO) is caused by reactivation of VZV after a primary infection. Since the introduction of routine varicella vaccination in children there has been an increased incidence of HZO which has been attributed to a lack of passive natural immune boost against the virus.¹⁰⁴ At this time the recommendation is to vaccinate all older adults with the zoster vaccine to prevent HZO and other zoster infections. The Zoster Eye Disease Study will investigate the extended use of oral valacyclovir for the prophylaxis of VZV keratitis.

FUTURE DIRECTIONS

Next Generation Sequencing

Culture negative keratitis remains a significant problem for clinicians. At Aravind Eye Hospital in India, for example, 38% of corneal scrapings from eyes with presumed infectious keratitis tested negative on both culture and smear between 2002 and 2012.¹⁰⁵ Next Generation Sequencing (NGS) may improve on the diagnostic accuracy of infectious keratitis, particularly for organisms that are difficult to culture by conventional methods such as atypical or anaerobic bacteria.¹⁰⁶ NGS can detect more organisms than traditional culture techniques, and provide us with large volumes of information about the microbiome of the ocular surface. However, it is not clear whether these approaches can be used to effectively determine the etiology of infection or antibiotic sensitivity data.¹⁰⁷

Collagen Cross-Linking for Bacterial and Fungal Keratitis

Collagen cross-linking (CXL) is a treatment in which photo-chemically activated riboflavin promotes the formation of covalent bonds between collagen molecules in the cornea. CXL helps strengthen corneal tissue, and is currently used to treat keratoconus and other corneal ectatic disorders.^{108–111} CXL may be beneficial in the treatment of infectious ulcers due to

its direct antimicrobial effects and its potential to improve the cornea's resistance to enzymatic degradation.¹¹²

In vitro studies have shown UV-A light plus riboflavin to be effective against many bacterial pathogens that cause corneal ulcers.¹¹³ Additionally, a number of case reports have shown CXL to be potentially beneficial in the treatment of recalcitrant bacterial and fungal keratitis, with effects including improvement of symptoms, the halting of progressive melting, and the resolution of treatment-resistant infections.^{107,114–116} One small case series treated 16 patients with bacterial keratitis exclusively with CXL.¹¹⁷ Fourteen of those patients' ulcers resolved with no further treatment; only 2 required topical antibiotics to clear the infection. If CXL could be used in place of antibiotic treatment this could help treat drug resistant infections and avoid ocular surface toxicity that currently can complicate the treatment of bacterial ulcers.

There is less robust evidence to support the use of CXL in treating filamentous fungal keratitis. *In vitro* CXL alone has not been shown to inactivate fungus, although one *in vitro* study did find CXL plus amphotericin to improve inhibition of fungal pathogens over amphotericin alone.^{113,118} Though there is not as much evidentiary support for using CXL to treat fungal keratitis, it is already in use in conjunction with antifungals by some clinicians hoping that it might add any benefit given the poor prognosis for fungal ulcers.

To date, three prospective clinical trials have been conducted to assess the effect of CXL in the treatment of infectious keratitis. Bamdad et al randomized 32 patients with moderate bacterial keratitis to receive either CXL plus standard therapy or standard therapy alone.¹¹⁹ Two weeks after the treatment, those receiving CXL had a lower mean grade of ulcer (0.69 vs 1.70; $P=0.001$), smaller area of epithelial defects ($P=0.001$), and smaller area of infiltrate ($P<0.001$) than those receiving the standard therapy alone. Mean treatment duration was also shorter in the CXL group ($P<0.001$).

Another trial randomized patients with bacterial, fungal, *Acanthamoeba*, or mixed origin keratitis to CXL versus antimicrobial treatment alone.¹²⁰ While this trial found no difference between groups, it had multiple issues, including inappropriate randomization, inclusion of patients with any kind of keratitis, and insufficient power.¹²¹ A third, small randomized clinical trial investigated cross-linking as adjuvant therapy for deep fungal ulcers at Aravind Eye Hospital in Madurai, India suggested that CXL could increase the rate of perforation in fungal ulcers.¹²²

Given the limitations of these clinical trials and mixed results, it is not known whether CXL is a beneficial adjuvant therapy for infectious keratitis. To date, the strongest case currently can be made for the use of CXL in treating bacterial keratitis. A larger scale, well-designed randomized clinical trial is needed in order to fully assess the utility of CXL for the treatment of infectious keratitis.

CONCLUSION

Despite having appropriate antimicrobial treatments for most of the pathogens implicated in infectious keratitis, clinical outcomes are often poor. Strategies to reduce the morbidity

associated with this condition are likely going to have to be multidimensional involving corneal ulcer prevention, improved early and accurate diagnostics techniques such as next generation sequencing as well as novel antimicrobial agents to address the development of drug resistance. Adjuvant therapies that focus on modifying the immune response to the infection thereby reducing the corneal melting and scarring which ultimately leads to poor vision, may have the greatest potential to improve clinical outcomes.

Acknowledgments

There are no conflicts of interest to declare. Individual support for this study came from K23 EY025025 (JRN), an unrestricted grant from the Peirles Foundation (JRN), and an unrestricted grant from Research to Prevent Blindness (JRN).

REFERENCES^{123–133}

- Whitcher JP, Srinivasan M, Upadhyay MP. Corneal blindness: a global perspective. *Bulletin of the World Health Organization*. 2001; 79(3):214–221. [PubMed: 11285665]
- Pascolini D, Mariotti SP. Global estimates of visual impairment: 2010. *The British journal of ophthalmology*. May; 2012 96(5):614–618. [PubMed: 22133988]
- WHO. [Accessed December 7, 2016] Causes of blindness and visual impairment. <http://www.who.int/blindness/causes/en>
- Gupta N, Tandon R, Gupta SK, Sreenivas V, Vashist P. Burden of corneal blindness in India. *Indian journal of community medicine: official publication of Indian Association of Preventive & Social Medicine*. Oct; 2013 38(4):198–206. [PubMed: 24302819]
- Gonzales CA, Srinivasan M, Whitcher JP, Smolin G. Incidence of corneal ulceration in Madurai district, South India. *Ophthalmic epidemiology*. Dec; 1996 3(3):159–166. [PubMed: 8956320]
- Dart JK, Stapleton F, Minassian D. Contact lenses and other risk factors in microbial keratitis. *Lancet*. Sep 14; 1991 338(8768):650–653. [PubMed: 1679472]
- Green M, Apel A, Stapleton F. Risk factors and causative organisms in microbial keratitis. *Cornea*. Jan; 2008 27(1):22–27. [PubMed: 18245962]
- Keay L, Stapleton F, Schein O. Epidemiology of contact lens-related inflammation and microbial keratitis: a 20-year perspective. *Eye & contact lens*. Nov; 2007 33(6 Pt 2):346–353. discussion 362–343. [PubMed: 17975418]
- Thylefors B. Epidemiological patterns of ocular trauma. *Australian and New Zealand journal of ophthalmology*. May; 1992 20(2):95–98. [PubMed: 1389141]
- Sheng XL, Li HP, Liu QX, et al. Prevalence and associated factors of corneal blindness in Ningxia in northwest China. *International journal of ophthalmology*. 2014; 7(3):557–562. [PubMed: 24967208]
- Saha S, Banerjee D, Khetan A, Sengupta J. Epidemiological profile of fungal keratitis in urban population of West Bengal, India. *Oman journal of ophthalmology*. Sep; 2009 2(3):114–118. [PubMed: 20927207]
- Nirmalan PK, Katz J, Tielsch JM, et al. Ocular trauma in a rural south Indian population: the Aravind Comprehensive Eye Survey. *Ophthalmology*. Sep; 2004 111(9):1778–1781. [PubMed: 15350336]
- McLeod SD, Kolahdouz-Isfahani A, Rostamian K, Flowers CW, Lee PP, McDonnell PJ. The role of smears, cultures, and antibiotic sensitivity testing in the management of suspected infectious keratitis. *Ophthalmology*. Jan; 1996 103(1):23–28. [PubMed: 8628555]
- Kim E, Chidambaram JD, Srinivasan M, et al. Prospective comparison of microbial culture and polymerase chain reaction in the diagnosis of corneal ulcer. *American journal of ophthalmology*. Nov; 2008 146(5):714–723. 723 e711. [PubMed: 18707670]
- Chang HY, Chodosh J. Diagnostic and therapeutic considerations in fungal keratitis. *International ophthalmology clinics*. Fall;2011 51(4):33–42.

16. Badiie P, Nejabat M, Alborzi A, Keshavarz F, Shakiba E. Comparative study of Gram stain, potassium hydroxide smear, culture and nested PCR in the diagnosis of fungal keratitis. *Ophthalmic research*. 2010; 44(4):251–256. [PubMed: 20699629]
17. Zhang W, Yang H, Jiang L, Han L, Wang L. Use of potassium hydroxide, Giemsa and calcofluor white staining techniques in the microscopic evaluation of corneal scrapings for diagnosis of fungal keratitis. *The Journal of international medical research*. 2010; 38(6):1961–1967. [PubMed: 21226999]
18. Gopinathan U, Sharma S, Garg P, Rao GN. Review of epidemiological features, microbiological diagnosis and treatment outcome of microbial keratitis: experience of over a decade. *Indian journal of ophthalmology*. Jul-Aug;2009 57(4):273–279. [PubMed: 19574694]
19. 2013 ABKP. Bacterial Keratitis Preferred Practice Pattern (PPP) Guideline. American Academy of Ophthalmology; 2013.
20. Darougar S, Wishart MS, Viswalingam ND. Epidemiological and clinical features of primary herpes simplex virus ocular infection. *The British journal of ophthalmology*. Jan; 1985 69(1):2–6. [PubMed: 3965025]
21. El-Aal AM, El Sayed M, Mohammed E, Ahmed M, Fathy M. Evaluation of herpes simplex detection in corneal scrapings by three molecular methods. *Current microbiology*. May; 2006 52(5):379–382. [PubMed: 16586022]
22. Nielsen E, Heegaard S, Prause JU, Ivarsen A, Mortensen KL, Hjortdal J. Fungal keratitis - improving diagnostics by confocal microscopy. *Case reports in ophthalmology*. Sep; 2013 4(3): 303–310. [PubMed: 24474933]
23. Avunduk AM, Beuerman RW, Varnell ED, Kaufman HE. Confocal microscopy of *Aspergillus fumigatus* keratitis. *The British journal of ophthalmology*. Apr; 2003 87(4):409–410. [PubMed: 12642300]
24. Das S, Samant M, Garg P, Vaddavalli PK, Vemuganti GK. Role of confocal microscopy in deep fungal keratitis. *Cornea*. Jan; 2009 28(1):11–13. [PubMed: 19092397]
25. Kanavi MR, Javadi M, Yazdani S, Mirdehghanm S. Sensitivity and specificity of confocal scan in the diagnosis of infectious keratitis. *Cornea*. Aug; 2007 26(7):782–786. [PubMed: 17667609]
26. Vaddavalli PK, Garg P, Sharma S, Sangwan VS, Rao GN, Thomas R. Role of confocal microscopy in the diagnosis of fungal and acanthamoeba keratitis. *Ophthalmology*. Jan; 2011 118(1):29–35. [PubMed: 20801515]
27. Konstantopoulos A, Kuo J, Anderson D, Hossain P. Assessment of the use of anterior segment optical coherence tomography in microbial keratitis. *American journal of ophthalmology*. Oct; 2008 146(4):534–542. [PubMed: 18602080]
28. Martone G, Pichierrri P, Franceschini R, et al. In vivo confocal microscopy and anterior segment optical coherence tomography in a case of alternaria keratitis. *Cornea*. Apr; 2011 30(4):449–453. [PubMed: 21099420]
29. Austin A, Schallhorn J, Geske M, Mannis M, Lietman T, Rose-Nussbaumer J. Empiric Treatment of Bacterial Keratitis: An International Survey of Corneal Specialists. *British Journal of Ophthalmology Open*. in-press.
30. McDonald EM, Ram FS, Patel DV, McGhee CN. Topical antibiotics for the management of bacterial keratitis: an evidence-based review of high quality randomised controlled trials. *The British journal of ophthalmology*. Nov; 2014 98(11):1470–1477. [PubMed: 24729078]
31. Constantinou M, Daniell M, Snibson GR, Vu HT, Taylor HR. Clinical efficacy of moxifloxacin in the treatment of bacterial keratitis: a randomized clinical trial. *Ophthalmology*. Sep; 2007 114(9): 1622–1629. [PubMed: 17822972]
32. O'Brien TP, Maguire MG, Fink NE, Alfonso E, McDonnell P. Efficacy of ofloxacin vs cefazolin and tobramycin in the therapy for bacterial keratitis. Report from the Bacterial Keratitis Study Research Group. *Archives of ophthalmology*. Oct; 1995 113(10):1257–1265. [PubMed: 7575256]
33. Hyndiuk RA, Eiferman RA, Caldwell DR, et al. Comparison of ciprofloxacin ophthalmic solution 0.3% to fortified tobramycin-cefazolin in treating bacterial corneal ulcers. Ciprofloxacin Bacterial Keratitis Study Group. *Ophthalmology*. Nov; 1996 103(11):1854–1862. discussion 1862-1853. [PubMed: 8942881]

34. Pavesio CMN, Allan B, El Kassaby H, DeCock R. Ofloxacin monotherapy for the primary treatment of microbial keratitis: a double-masked, randomized, controlled trial with conventional dual therapy. The Ofloxacin Study Group. *Ophthalmology*. Nov; 1997 104(11):1902–1909. [PubMed: 9373124]
35. Team EE. CDC publishes report on antibiotic resistance threats in the United States for the first time. *Eurosurveillance*. Sep 19; 2013 18(38):28–28.
36. Asbell PA, Colby KA, Deng S, et al. Ocular TRUST: nationwide antimicrobial susceptibility patterns in ocular isolates. *American journal of ophthalmology*. Jun; 2008 145(6):951–958. [PubMed: 18374299]
37. Haas W, Pillar CM, Torres M, Morris TW, Sahn DF. Monitoring antibiotic resistance in ocular microorganisms: results from the Antibiotic Resistance Monitoring in Ocular micRorganisms (ARMOR) 2009 surveillance study. *American journal of ophthalmology*. Oct; 2011 152(4):567–574. e563. [PubMed: 21652021]
38. Alster Y, Herlin L, Lazar M, Loewenstein A. Intraocular penetration of vancomycin eye drops after application to the medial canthus with closed lids. *The British journal of ophthalmology*. Mar; 2000 84(3):300–302. [PubMed: 10684842]
39. Ray KJ, Prajna L, Srinivasan M, et al. Fluoroquinolone treatment and susceptibility of isolates from bacterial keratitis. *JAMA ophthalmology*. Mar; 2013 131(3):310–313. [PubMed: 23307105]
40. Oldenburg CE, Lalitha P, Srinivasan M, et al. Moxifloxacin susceptibility mediates the relationship between causative organism and clinical outcome in bacterial keratitis. *Investigative ophthalmology & visual science*. Feb; 2013 54(2):1522–1526. [PubMed: 23385795]
41. Lalitha P, Srinivasan M, Manikandan P, et al. Relationship of in vitro susceptibility to moxifloxacin and in vivo clinical outcome in bacterial keratitis. *Clinical infectious diseases: an official publication of the Infectious Diseases Society of America*. May; 2012 54(10):1381–1387. [PubMed: 22447793]
42. Burns FR, Stack MS, Gray RD, Paterson CA. Inhibition of purified collagenase from alkali-burned rabbit corneas. *Investigative ophthalmology & visual science*. Jul; 1989 30(7):1569–1575. [PubMed: 2545645]
43. Golub LM, Sorsa T, Lee HM, et al. Doxycycline inhibits neutrophil (PMN)-type matrix metalloproteinases in human adult periodontitis gingiva. *J Clin Periodontol*. Feb; 1995 22(2):100–109. [PubMed: 7775665]
44. Dursun D, Kim MC, Solomon A, Pflugfelder SC. Treatment of recalcitrant recurrent corneal erosions with inhibitors of matrix metalloproteinase-9, doxycycline and corticosteroids. *American journal of ophthalmology*. Jul; 2001 132(1):8–13. [PubMed: 11438047]
45. Seedor JA, Perry HD, McNamara TF, Golub LM, Buxton DF, Guthrie DS. Systemic tetracycline treatment of alkali-induced corneal ulceration in rabbits. *Arch Ophthalmol*. Feb; 1987 105(2):268–271. [PubMed: 3813962]
46. Levy JH, Katz HR. Effect of systemic tetracycline on progression of *Pseudomonas aeruginosa* keratitis in the rabbit. *Ann Ophthalmol*. May; 1990 22(5):179–183. [PubMed: 2114813]
47. Acharya NR, Srinivasan M, Mascarenhas J, et al. The steroid controversy in bacterial keratitis. *Archives of ophthalmology*. Sep; 2009 127(9):1231. [PubMed: 19752446]
48. Cohen EJ. The case against the use of steroids in the treatment of bacterial keratitis. *Archives of ophthalmology*. Jan; 2009 127(1):103–104. [PubMed: 19139349]
49. Hindman HB, Patel SB, Jun AS. Rationale for adjunctive topical corticosteroids in bacterial keratitis. *Archives of ophthalmology*. Jan; 2009 127(1):97–102. [PubMed: 19139348]
50. Den S, Sotozono C, Kinoshita S, Ikeda T. Efficacy of early systemic betamethasone or cyclosporin A after corneal alkali injury via inflammatory cytokine reduction. *Acta ophthalmologica Scandinavica*. Apr; 2004 82(2):195–199. [PubMed: 15043540]
51. Yi K, Chung TY, Hyon JY, Koh JW, Wee WR, Shin YJ. Combined treatment with antioxidants and immunosuppressants on cytokine release by human peripheral blood mononuclear cells - chemically injured keratocyte reaction. *Molecular vision*. 2011; 17:2665–2671. [PubMed: 22065919]
52. Williams RN, Paterson CA. The influence of topical corticosteroid therapy upon polymorphonuclear leukocyte distribution, vascular integrity and ascorbate levels in endotoxin-

- induced inflammation of the rabbit eye. *Experimental eye research*. Feb; 1987 44(2):191–198. [PubMed: 3582506]
53. Chung JH, Kang YG, Kim HJ. Effect of 0.1% dexamethasone on epithelial healing in experimental corneal alkali wounds: morphological changes during the repair process. *Graefe's archive for clinical and experimental ophthalmology = Albrecht von Graefes Archiv fur klinische und experimentelle Ophthalmologie*. Jul; 1998 236(7):537–545.
 54. Tomas-Barberan S, Fagerholm P. Influence of topical treatment on epithelial wound healing and pain in the early postoperative period following photorefractive keratectomy. *Acta ophthalmologica Scandinavica*. Apr; 1999 77(2):135–138. [PubMed: 10321525]
 55. Gritz DC, Kwitko S, Trousdale MD, Gonzalez VH, McDonnell PJ. Recurrence of microbial keratitis concomitant with antiinflammatory treatment in an animal model. *Cornea*. Sep; 1992 11(5):404–408. [PubMed: 1424668]
 56. Gritz DC, Lee TY, Kwitko S, McDonnell PJ. Topical anti-inflammatory agents in an animal model of microbial keratitis. *Archives of ophthalmology*. Jul; 1990 108(7):1001–1005. [PubMed: 2369336]
 57. Herretes S, Wang X, Reyes JM. Topical corticosteroids as adjunctive therapy for bacterial keratitis. *The Cochrane database of systematic reviews*. Oct 16.2014 (10):CD005430. [PubMed: 25321340]
 58. Blair J, Hodge W, Al-Ghamdi S, et al. Comparison of antibiotic-only and antibiotic-steroid combination treatment in corneal ulcer patients: double-blinded randomized clinical trial. *Canadian journal of ophthalmology. Journal canadien d'ophthalmologie*. Feb; 2011 46(1):40–45.
 59. Carmichael TR, Gelfand Y, Welsh NH. Topical steroids in the treatment of central and paracentral corneal ulcers. *The British journal of ophthalmology*. Sep; 1990 74(9):528–531. [PubMed: 2203467]
 60. Srinivasan M, Lalitha P, Mahalakshmi R, et al. Corticosteroids for bacterial corneal ulcers. *The British journal of ophthalmology*. Feb; 2009 93(2):198–202. [PubMed: 18829631]
 61. Srinivasan M, Mascarenhas J, Rajaraman R, et al. Corticosteroids for bacterial keratitis: the Steroids for Corneal Ulcers Trial (SCUT). *Archives of ophthalmology*. Feb; 2012 130(2):143–150. [PubMed: 21987582]
 62. Ray KJ, Srinivasan M, Mascarenhas J, et al. Early addition of topical corticosteroids in the treatment of bacterial keratitis. *JAMA ophthalmology*. Jun; 2014 132(6):737–741. [PubMed: 24763755]
 63. Lalitha P, Srinivasan M, Rajaraman R, et al. Nocardia keratitis: clinical course and effect of corticosteroids. *American journal of ophthalmology*. Dec; 2012 154(6):934–939. e931. [PubMed: 22959881]
 64. Srinivasan M, Mascarenhas J, Rajaraman R, et al. The steroids for corneal ulcers trial (SCUT): secondary 12-month clinical outcomes of a randomized controlled trial. *American journal of ophthalmology*. Feb; 2014 157(2):327–333. e323. [PubMed: 24315294]
 65. Borkar DS, Fleiszig SM, Leong C, et al. Association between cytotoxic and invasive *Pseudomonas aeruginosa* and clinical outcomes in bacterial keratitis. *JAMA ophthalmology*. Feb; 2013 131(2):147–153. [PubMed: 23411878]
 66. Gopinathan U, Garg P, Fernandes M, Sharma S, Athmanathan S, Rao GN. The epidemiological features and laboratory results of fungal keratitis: a 10-year review at a referral eye care center in South India. *Cornea*. Aug; 2002 21(6):555–559. [PubMed: 12131029]
 67. Deorukhkar S, Katiyar R, Saini S. Epidemiological features and laboratory results of bacterial and fungal keratitis: a five-year study at a rural tertiary-care hospital in western Maharashtra, India. *Singapore medical journal*. Apr; 2012 53(4):264–267. [PubMed: 22511050]
 68. Srinivasan M, Gonzales CA, George C, et al. Epidemiology and aetiological diagnosis of corneal ulceration in Madurai, south India. *The British journal of ophthalmology*. Nov; 1997 81(11):965–971. [PubMed: 9505820]
 69. Alfonso E, Mandelbaum S, Fox MJ, Forster RK. Ulcerative keratitis associated with contact lens wear. *American journal of ophthalmology*. Apr 15; 1986 101(4):429–433. [PubMed: 3963102]
 70. Bernal MD, Acharya NR, Lietman TM, Strauss EC, McLeod SD, Hwang DG. Outbreak of *Fusarium* keratitis in soft contact lens wearers in San Francisco. *Archives of ophthalmology*. Jul; 2006 124(7):1051–1053. [PubMed: 16769826]

71. Gower EW, Keay LJ, Oechsler RA, et al. Trends in fungal keratitis in the United States, 2001 to 2007. *Ophthalmology*. Dec; 2010 117(12):2263–2267. [PubMed: 20591493]
72. Tanure MA, Cohen EJ, Sudesh S, Rapuano CJ, Laibson PR. Spectrum of fungal keratitis at Wills Eye Hospital, Philadelphia, Pennsylvania. *Cornea*. May; 2000 19(3):307–312. [PubMed: 10832689]
73. O'Day DM, Head WS, Robinson RD, Clanton JA. Corneal penetration of topical amphotericin B and natamycin. *Current eye research*. Nov; 1986 5(11):877–882. [PubMed: 3490954]
74. Hariprasad SM, Mieler WF, Lin TK, Sponsel WE, Graybill JR. Voriconazole in the treatment of fungal eye infections: a review of current literature. *The British journal of ophthalmology*. Jul; 2008 92(7):871–878. [PubMed: 18577634]
75. Walsh TJ, Pappas P, Winston DJ, et al. Voriconazole compared with liposomal amphotericin B for empirical antifungal therapy in patients with neutropenia and persistent fever. *The New England journal of medicine*. Jan 24; 2002 346(4):225–234. [PubMed: 11807146]
76. Prajna NV, Krishnan T, Mascarenhas J, et al. The mycotic ulcer treatment trial: a randomized trial comparing natamycin vs voriconazole. *JAMA ophthalmology*. Apr; 2013 131(4):422–429. [PubMed: 23710492]
77. Sharma S, Das S, Viridi A, et al. Re-appraisal of topical 1% voriconazole and 5% natamycin in the treatment of fungal keratitis in a randomised trial. *The British journal of ophthalmology*. Sep; 2015 99(9):1190–1195. [PubMed: 25740805]
78. FlorCruz NV, Evans JR. Medical interventions for fungal keratitis. *The Cochrane database of systematic reviews*. 2015; (4):CD004241. [PubMed: 25855311]
79. Thiel MA, Zinkernagel AS, Burhenne J, Kaufmann C, Haefeli WE. Voriconazole concentration in human aqueous humor and plasma during topical or combined topical and systemic administration for fungal keratitis. *Antimicrobial agents and chemotherapy*. Jan; 2007 51(1):239–244. [PubMed: 17060517]
80. Hernandez Prats C, Llinares Tello F, Burgos San Jose A, Selva Otaolaurruchi J, Ordovas Baines JP. Voriconazole in fungal keratitis caused by *Scedosporium apiospermum*. *The Annals of pharmacotherapy*. Mar; 2004 38(3):414–417. [PubMed: 14755065]
81. Jones A, Muhtaseb M. Use of voriconazole in fungal keratitis. *Journal of cataract and refractive surgery*. Feb; 2008 34(2):183–184. [PubMed: 18242428]
82. Prajna NV, Krishnan T, Rajaraman R, et al. Effect of Oral Voriconazole on Fungal Keratitis in the Mycotic Ulcer Treatment Trial II (MUTT II): A Randomized Clinical Trial. *JAMA ophthalmology*. Oct 27.2016
83. Sharma B, Kataria P, Anand R, et al. Efficacy Profile of Intracameral Amphotericin B. *The Often Forgotten Step*. *Asia-Pacific journal of ophthalmology*. Nov-Dec;2015 4(6):360–366. [PubMed: 26181588]
84. Yoon KC, Jeong IY, Im SK, Chae HJ, Yang SY. Therapeutic effect of intracameral amphotericin B injection in the treatment of fungal keratitis. *Cornea*. Aug; 2007 26(7):814–818. [PubMed: 17667615]
85. Kaushik S, Ram J, Brar GS, Jain AK, Chakraborti A, Gupta A. Intracameral amphotericin B: initial experience in severe keratomycosis. *Cornea*. Oct; 2001 20(7):715–719. [PubMed: 11588423]
86. Kuriakose T, Kothari M, Paul P, Jacob P, Thomas R. Intracameral amphotericin B injection in the management of deep keratomycosis. *Cornea*. Oct; 2002 21(7):653–656. [PubMed: 12352080]
87. Sharma N, Sankaran P, Agarwal T, et al. Evaluation of Intracameral Amphotericin B in the Management of Fungal Keratitis: Randomized Controlled Trial. *Ocular immunology and inflammation*. Oct; 2016 24(5):493–497. [PubMed: 26400628]
88. Kalaiselvi G, Narayana S, Krishnan T, Sengupta S. Intrastromal voriconazole for deep recalcitrant fungal keratitis: a case series. *The British journal of ophthalmology*. Feb; 2015 99(2):195–198. [PubMed: 25185253]
89. Prakash G, Sharma N, Goel M, Titiyal JS, Vajpayee RB. Evaluation of intrastromal injection of voriconazole as a therapeutic adjunctive for the management of deep recalcitrant fungal keratitis. *American journal of ophthalmology*. Jul; 2008 146(1):56–59. [PubMed: 18436173]

90. Sharma N, Agarwal P, Sinha R, Titiyal JS, Velpandian T, Vajpayee RB. Evaluation of intrastromal voriconazole injection in recalcitrant deep fungal keratitis: case series. *The British journal of ophthalmology*. Dec; 2011 95(12):1735–1737. [PubMed: 21454381]
91. Farooq AV, Shukla D. Herpes simplex epithelial and stromal keratitis: an epidemiologic update. *Survey of ophthalmology*. Sep; 2012 57(5):448–462. [PubMed: 22542912]
92. Liesegang TJ, Melton LJ 3rd, Daly PJ, Ilstrup DM. Epidemiology of ocular herpes simplex. Incidence in Rochester, Minn, 1950 through 1982. *Archives of ophthalmology*. Aug; 1989 107(8): 1155–1159. [PubMed: 2787981]
93. Reynaud C, Rousseau A, Kaswin G, M'Garrech M, Barreau E, Labetoulle M. Persistent Impairment of Quality of Life in Patients with Herpes Simplex Keratitis. *Ophthalmology*. Feb; 2017 124(2):160–169. [PubMed: 27863844]
94. Morfin F, Thouvenot D. Herpes simplex virus resistance to antiviral drugs. *Journal of clinical virology: the official publication of the Pan American Society for Clinical Virology*. Jan; 2003 26(1):29–37. [PubMed: 12589832]
95. Tsatsos M, MacGregor C, Athanasiadis I, Moschos MM, Hossain P, Anderson D. Herpes simplex virus keratitis: an update of the pathogenesis and current treatment with oral and topical antiviral agents. *Clinical & experimental ophthalmology*. Dec; 2016 44(9):824–837. [PubMed: 27273328]
96. Chou TY, Hong BY. Ganciclovir ophthalmic gel 0.15% for the treatment of acute herpetic keratitis: background, effectiveness, tolerability, safety, and future applications. *Therapeutics and clinical risk management*. 2014; 10:665–681. [PubMed: 25187721]
97. Colin J, Hoh HB, Easty DL, et al. Ganciclovir ophthalmic gel (Virgan; 0.15%) in the treatment of herpes simplex keratitis. *Cornea*. Jul; 1997 16(4):393–399. [PubMed: 9220235]
98. Wilhelmus KR, Gee L, Hauck WW, et al. Herpetic Eye Disease Study. A controlled trial of topical corticosteroids for herpes simplex stromal keratitis. *Ophthalmology*. Dec; 1994 101(12):1883–1895. discussion 1895-1886. [PubMed: 7997324]
99. Barron BA, Gee L, Hauck WW, et al. Herpetic Eye Disease Study. A controlled trial of oral acyclovir for herpes simplex stromal keratitis. *Ophthalmology*. Dec; 1994 101(12):1871–1882. [PubMed: 7997323]
100. Goldblum D, Bachmann C, Tappeiner C, Garweg J, Frueh BE. Comparison of oral antiviral therapy with valacyclovir or acyclovir after penetrating keratoplasty for herpetic keratitis. *The British journal of ophthalmology*. Sep; 2008 92(9):1201–1205. [PubMed: 18650215]
101. Dias C, Nashed Y, Atluri H, Mitra A. Ocular penetration of acyclovir and its peptide prodrugs valacyclovir and val-valacyclovir following systemic administration in rabbits: An evaluation using ocular microdialysis and LC-MS. *Current eye research*. Oct; 2002 25(4):243–252. [PubMed: 12658558]
102. Razonable RR. Antiviral drugs for viruses other than human immunodeficiency virus. *Mayo Clinic proceedings*. Oct; 2011 86(10):1009–1026. [PubMed: 21964179]
103. Herpetic Eye Disease Study Group. Acyclovir for the prevention of recurrent herpes simplex virus eye disease. *The New England journal of medicine*. Jul 30; 1998 339(5):300–306. [PubMed: 9696640]
104. Thomas SL, Wheeler JG, Hall AJ. Contacts with varicella or with children and protection against herpes zoster in adults: a case-control study. *Lancet*. Aug 31; 2002 360(9334):678–682. [PubMed: 12241874]
105. Lalitha P, Prajna NV, Manoharan G, et al. Trends in bacterial and fungal keratitis in South India, 2002–2012. *The British journal of ophthalmology*. Feb; 2015 99(2):192–194. [PubMed: 25143391]
106. Papaioannou L, Miligkos M, Papathanassiou M. Corneal Collagen Cross-Linking for Infectious Keratitis: A Systematic Review and Meta-Analysis. *Cornea*. Jan; 2016 35(1):62–71. [PubMed: 26509768]
107. Iseli HP, Thiel MA, Hafezi F, Kampmeier J, Seiler T. Ultraviolet A/riboflavin corneal cross-linking for infectious keratitis associated with corneal melts. *Cornea*. Jun; 2008 27(5):590–594. [PubMed: 18520510]
108. Keating A, Pineda R 2nd, Colby K. Corneal cross linking for keratoconus. *Seminars in ophthalmology*. Sep-Nov; 2010 25(5–6):249–255. [PubMed: 21091008]

109. Lamy R, Netto CF, Reis RG, et al. Effects of corneal cross-linking on contrast sensitivity, visual acuity, and corneal topography in patients with keratoconus. *Cornea*. May; 2013 32(5):591–596. [PubMed: 23023410]
110. Raiskup-Wolf F, Hoyer A, Spoerl E, Pillunat LE. Collagen crosslinking with riboflavin and ultraviolet-A light in keratoconus: long-term results. *Journal of cataract and refractive surgery*. May; 2008 34(5):796–801. [PubMed: 18471635]
111. Vinciguerra P, Albe E, Trazza S, Seiler T, Epstein D. Intraoperative and postoperative effects of corneal collagen cross-linking on progressive keratoconus. *Archives of ophthalmology*. Oct; 2009 127(10):1258–1265. [PubMed: 19822840]
112. Alio JL, Abbouda A, Valle DD, Del Castillo JM, Fernandez JA. Corneal cross linking and infectious keratitis: a systematic review with a meta-analysis of reported cases. *Journal of ophthalmic inflammation and infection*. May 29.2013 3(1):47. [PubMed: 23718849]
113. Martins SA, Combs JC, Noguera G, et al. Antimicrobial efficacy of riboflavin/UVA combination (365 nm) in vitro for bacterial and fungal isolates: a potential new treatment for infectious keratitis. *Investigative ophthalmology & visual science*. Aug; 2008 49(8):3402–3408. [PubMed: 18408193]
114. Panda A, Krishna SN, Kumar S. Photo-activated riboflavin therapy of refractory corneal ulcers. *Cornea*. Oct; 2012 31(10):1210–1213. [PubMed: 22710492]
115. Makdoui K, Mortensen J, Crafoord S. Infectious keratitis treated with corneal crosslinking. *Cornea*. Dec; 2010 29(12):1353–1358. [PubMed: 21102196]
116. Shetty R, Nagaraja H, Jayadev C, Shivanna Y, Kugar T. Collagen crosslinking in the management of advanced non-resolving microbial keratitis. *The British journal of ophthalmology*. Aug; 2014 98(8):1033–1035. [PubMed: 24711659]
117. Makdoui K, Mortensen J, Sorkhabi O, Malmvall BE, Crafoord S. UVA-riboflavin photochemical therapy of bacterial keratitis: a pilot study. *Graefe's archive for clinical and experimental ophthalmology = Albrecht von Graefes Archiv fur klinische und experimentelle Ophthalmologie*. Jan; 2012 250(1):95–102.
118. Sauer A, Letscher-Bru V, Speeg-Schatz C, et al. In vitro efficacy of antifungal treatment using riboflavin/UV-A (365 nm) combination and amphotericin B. *Investigative ophthalmology & visual science*. Aug; 2010 51(8):3950–3953. [PubMed: 20335618]
119. Bamdad S, Malekhosseini H, Khosravi A. Ultraviolet A/riboflavin collagen cross-linking for treatment of moderate bacterial corneal ulcers. *Cornea*. Apr; 2015 34(4):402–406. [PubMed: 25710507]
120. Said DG, Elalfy MS, Gatziofias Z, et al. Collagen cross-linking with photoactivated riboflavin (PACK-CXL) for the treatment of advanced infectious keratitis with corneal melting. *Ophthalmology*. Jul; 2014 121(7):1377–1382. [PubMed: 24576886]
121. Mittal R, Garg P. Re: Said et al.: Collagen cross-linking with photoactivated riboflavin (PACK-CXL) for the treatment of advanced infectious keratitis with corneal melting (*Ophthalmology* 2014;121:1377–82). *Ophthalmology*. Dec; 2014 121(12):e67–68. [PubMed: 25459466]
122. Uddaraju M, Mascarenhas J, Das MR, et al. Corneal Cross-linking as an Adjuvant Therapy in the Management of Recalcitrant Deep Stromal Fungal Keratitis: A Randomized Trial. *American journal of ophthalmology*. Jul; 2015 160(1):131–134. e135. [PubMed: 25841317]
123. Booranapong W, Kosrirukvongs P, Prabhasawat P, Srivannaboon S, Suttiprakarn P. Comparison of topical lomefloxacin 0.3 per cent versus topical ciprofloxacin 0.3 per cent for the treatment of presumed bacterial corneal ulcers. *Journal of the Medical Association of Thailand = Chotmaihet thangphaet*. Mar; 2004 87(3):246–254. [PubMed: 15117040]
124. Dehghani AR, Fazel F, Akhlaghi MR, Ghanbari H, Ilanloo MR, Ahmadi-Azad D. Cefazolin-Gentamicin versus Vancomycin-Ceftazidime Eye Drops for Bacterial Corneal Ulcers;a Randomized Clinical Trial. *Journal of ophthalmic & vision research*. Jan; 2009 4(1):19–23. [PubMed: 23056669]
125. Erjongmanee S, Kasetsuwan N, Phusitphoykai N, Puangsricharern V, Pariyakanok L. Clinical evaluation of ophthalmic lomefloxacin 0.3% in comparison with fortified cefazolin and gentamicin ophthalmic solutions in the treatment of presumed bacterial keratitis. *Journal of the*

- Medical Association of Thailand = Chotmaihet thangkaet. Sep; 2004 87(Suppl 2):S83–90. [PubMed: 16083168]
126. Kasetsuwan NTP, Reinprayoon U. The efficacy and safety of 0.5% Levofloxacin versus fortified Cefazolin and Amikacin ophthalmic solution for the treatment of suspected and culture-proven cases of infectious bacterial keratitis: a comparative study. *Asian Biomedicine*. 2011; 5(1):77–83.
 127. Kosrirukvongs P, Buranapongs W. Topical ciprofloxacin for bacterial corneal ulcer. *Journal of the Medical Association of Thailand = Chotmaihet thangkaet*. Jul; 2000 83(7):776–782. [PubMed: 10932513]
 128. Panda A, Ahuja R, Sastry SS. Comparison of topical 0.3% ofloxacin with fortified tobramycin plus cefazolin in the treatment of bacterial keratitis. *Eye*. Dec; 1999 13(Pt 6):744–747. [PubMed: 10707137]
 129. Parmar P, Salman A, Kalavathy CM, et al. Comparison of topical gatifloxacin 0.3% and ciprofloxacin 0.3% for the treatment of bacterial keratitis. *American journal of ophthalmology*. Feb; 2006 141(2):282–286. [PubMed: 16458681]
 130. Prajna NV, George C, Selvaraj S, Lu KL, McDonnell PJ, Srinivasan M. Bacteriologic and clinical efficacy of ofloxacin 0.3% versus ciprofloxacin 0.3% ophthalmic solutions in the treatment of patients with culture-positive bacterial keratitis. *Cornea*. Mar; 2001 20(2):175–178. [PubMed: 11248824]
 131. Shah VM, Tandon R, Satpathy G, et al. Randomized clinical study for comparative evaluation of fourth-generation fluoroquinolones with the combination of fortified antibiotics in the treatment of bacterial corneal ulcers. *Cornea*. Jul; 2010 29(7):751–757. [PubMed: 20489580]
 132. Sharma N, Goel M, Bansal S, et al. Evaluation of moxifloxacin 0.5% in treatment of nonperforated bacterial corneal ulcers: a randomized controlled trial. *Ophthalmology*. Jun; 2013 120(6):1173–1178. [PubMed: 23415776]
 133. Prajna NV, Mascarenhas J, Krishnan T, et al. Comparison of natamycin and voriconazole for the treatment of fungal keratitis. *Archives of ophthalmology*. Jun; 2010 128(6):672–678. [PubMed: 20547942]

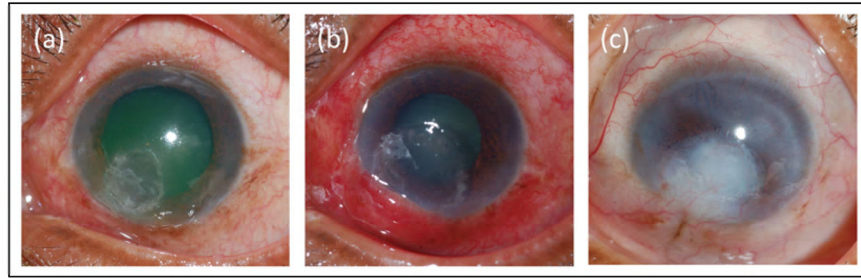


Figure 1.

A 64-year-old male manual laborer enrolled in SCUT whose ulcer was culture positive for *Nocardia* was randomized to adjuvant corticosteroids. (a) at enrollment his visual acuity was logMAR 1.2 (Snellen ~ 20/317); (b) at 3 weeks his visual acuity was logMAR 1.46 (Snellen ~20/577); (c) at 12 months his visual acuity continued to decline to 1.9 logMAR (Snellen LP).

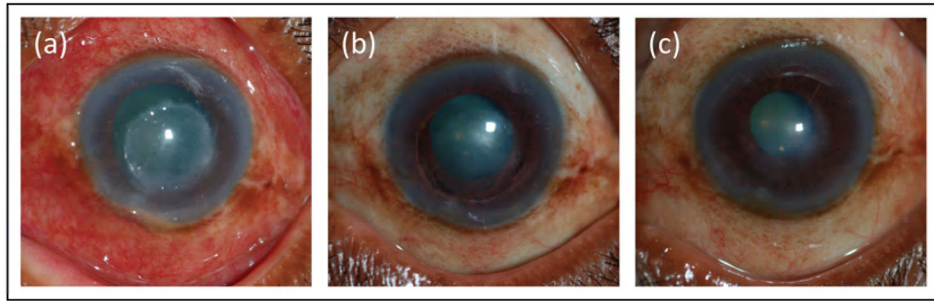


Figure 2.

A 67-year-old male manual laborer enrolled in SCUT whose ulcer was culture positive for *Pseudomonas aeruginosa* was randomized to adjuvant corticosteroids. (a) at enrollment his visual acuity was logMAR 1.7 (Snellen CF); (b) at 3 weeks his visual acuity was logMAR 0.62 (Snellen ~20/83); (c) at 12 months his visual acuity further improved to 0.24 logMAR (Snellen ~20/35) with contact lens over refraction.

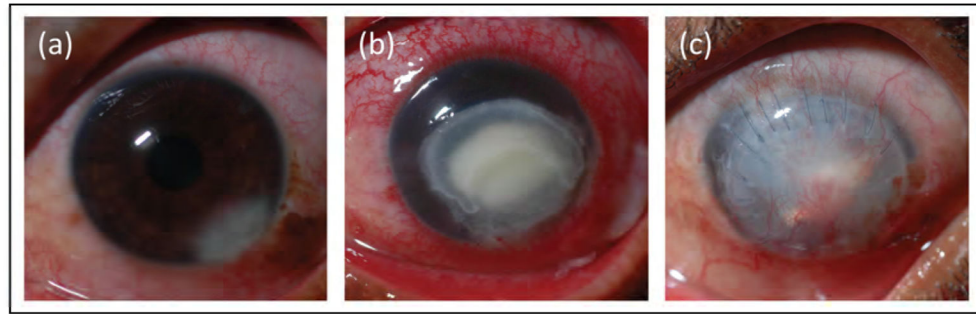


Figure 3.

A 32-year-old male tractor driver enrolled in MUTT I whose ulcer was culture positive for *Fusarium* was randomized to receive topical voriconazole. (a) at enrollment his visual acuity was logMAR 0.1 (Snellen ~20/25); (b) at 3 weeks his visual acuity was logMAR 1.8 (Snellen HM); (c) at 3 months he had perforated and undergone therapeutic penetrating keratoplasty, and his resulting visual acuity was logMAR 1.9 (Snellen LP) with contact lens over refraction.

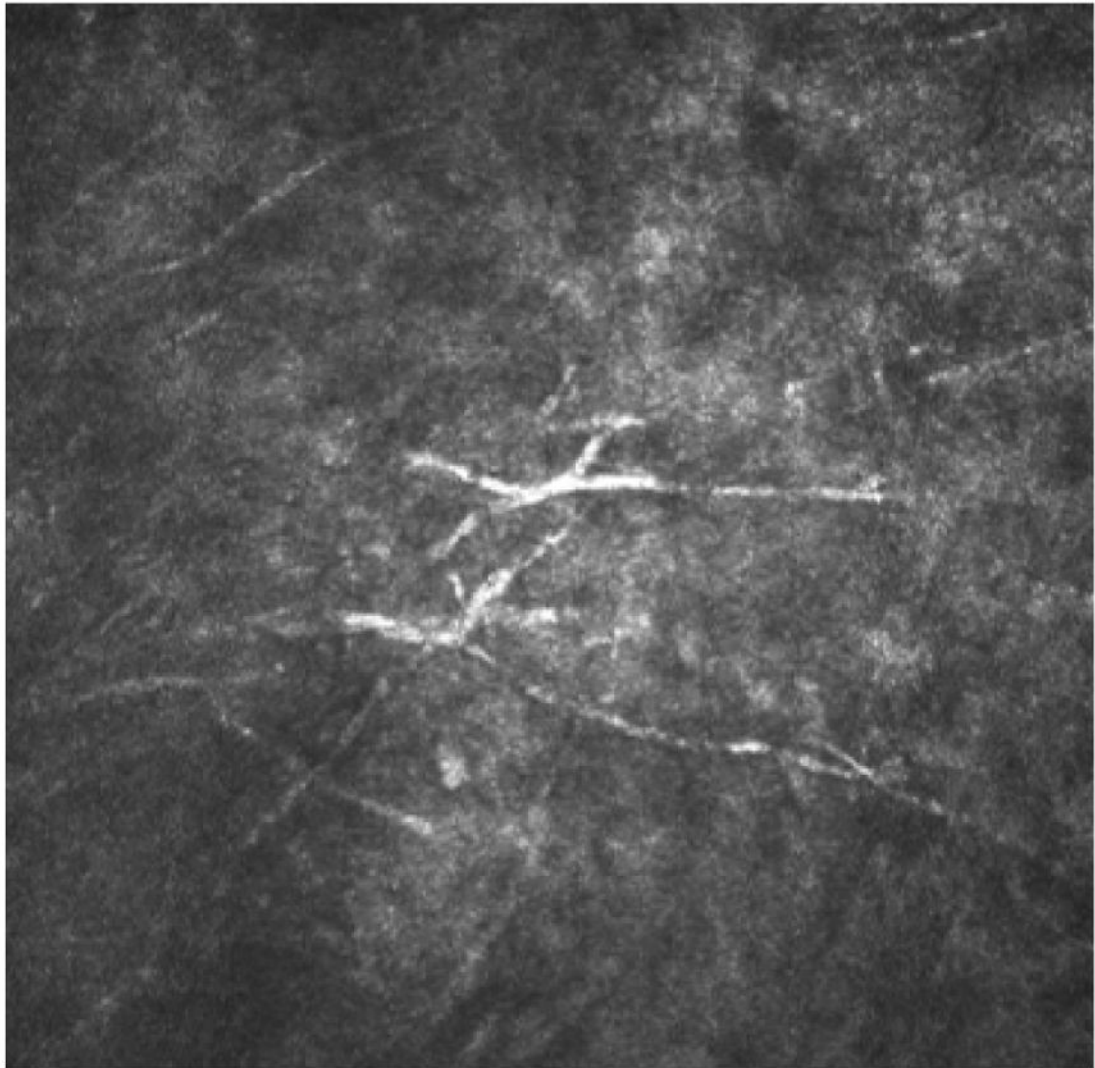


Image 1.
Confocal microscopy image from a patient with filamentous fungal keratitis.

Table 1a
Relevant randomized clinical trials (English-language, full text available online)

Trial	Question	N	Finding	Comment
Bacterial Keratitis				
Constantinou et al., 2007 ³¹	Moxifloxacin vs ofloxacin vs tobramycin/cefazolin	229	All treatments resulted in similar outcomes and rates of adverse events	Single-masked, vague primary outcome
Dehghani et al., 2009 ¹²⁴	Cefazolin/gentamicin vs vancomycin/ceftazidime	89	Vancomycin/cefazidime led to better outcomes and was better tolerated	Randomization method unclear, masking method unclear
Hyndiuk et al., 1996 ³³	Ciprofloxacin vs tobramycin/cefazolin	324	Both treatments resulted in similar outcomes, but ciprofloxacin resulted in fewer adverse events and less discomfort	No intent to treat analysis, uneven enrollment between arms
Kasetsuwan et al., 2011 ¹²⁶	Levofloxacin vs cefazolin/amikacin	71	Both treatments resulted in similar outcomes and rates of adverse events	Low baseline culture positivity, no intent to treat analysis, enrolled exclusively in Thailand*
O'Brien et al., 1995 ³²	Ofloxacin vs tobramycin/cefazolin	248	Both treatments resulted in similar outcomes, but ofloxacin led to less discomfort	No intent to treat analysis
Panda et al., 1999 ¹²⁸	Ofloxacin vs tobramycin/cefazolin	30	Both treatments resulted in similar outcomes and rates of adverse events	Small sample size, randomization method unclear, enrolled exclusively in Southeast Asia*
Antibiotic Treatment Trials				
Parmar et al., 2006 ¹²⁹	Gatifloxacin vs ciprofloxacin	104	Gatifloxacin resulted in complete healing more often than ciprofloxacin, and was more effective against	Enrolled exclusively in India*
Pavesio et al., 1997 ³⁴	Ofloxacin vs gentamicin/cefuroxime	122	Both treatments resulted in similar outcomes but ofloxacin resulted in less toxicity	Partially unmasked, enrolled exclusively in the United Kingdom*
Prajna et al., 2001 ¹³⁰	Ofloxacin vs ciprofloxacin	217	Both treatments resulted in similar outcomes and rates of adverse events	Vague primary outcome, enrolled exclusively in South India*
Shah et al., 2010 ³¹	Moxifloxacin vs gatifloxacin vs tobramycin/cefazolin	61	All treatments resulted in similar outcomes and rates of adverse events	Unmasked, small sample size, low baseline culture positivity, enrolled exclusively in India*
Sharma et al., 2013 ¹³²	Moxifloxacin vs tobramycin/cefazolin	224	Both treatments resulted in similar outcomes and rates of adverse events	Single-masked, unclear inclusion criteria, randomization allocation, and statistical analysis, enrolled exclusively in India*
Adjuvant Steroid Trials				
Blair et al., 2011 ⁵⁸	Adjuvant steroids vs placebo	30	Both treatments resulted in similar outcomes and rates of adverse events	Small sample size, conflicting results based on measurement methodology, enrolled exclusively in Canada*

Trial	Question	N	Finding	Comment
Carmichael et al., 1990 ⁵⁹	Adjuvant steroids vs standard therapy	40	Both treatments resulted in similar outcomes and rates of adverse events	Small sample size, enrolled exclusively in South Africa *
Srinivasan et al., 2009 ⁶⁰	Adjuvant steroids vs placebo	42	Both treatments resulted in similar outcomes and rates of adverse events	Small sample size, enrolled exclusively in India *
SCUTT ⁶¹	Adjuvant steroids vs placebo	500	No benefit of steroids overall; steroids did improve outcomes for those with low vision, central ulcers, deep ulcers, non- <i>Nocardia</i> or classically invasive <i>P. aeruginosa</i> ulcers, or early steroid administration	Enrolled few contact lens-related infections and enrolled exclusively in Southeast Asia *

* results may not be generalizable

Table 1b

Relevant randomized clinical trials (English-language, full text available online)

Trial	Question	N	Finding	Comment
Fungal Keratitis				
Prajna et al., 2010 ¹³³	Topical natamycin vs topical voriconazole	120	No significant difference between treatments	Enrolled exclusively in India *
MUTT I ⁷⁶	Topical natamycin vs topical voriconazole	323	Natamycin resulted in better BSCVA and fewer adverse events	Enrolled no contact lens-related infections and all patients were enrolled in South India *
Sharma et al., 2015 ⁷⁷	Topical natamycin vs topical voriconazole	118	Natamycin resulted in better BSCVA and fewer adverse events	Enrolled exclusively in India *
MUTT II ⁸²	Adjuvant oral voriconazole vs placebo	240	No benefit of adjuvant oral voriconazole	Only enrolled severe ulcers, enrolled few contact lens-related infections and all patients were enrolled in Southeast Asia *, regimen of topical drops changed during trial
Viral Keratitis				
HEDS I ⁹⁸	Adjuvant topical steroids vs placebo	106	Adjuvant corticosteroids resulted in faster resolution of infection and longer time to treatment failure	Only studied stromal HSV keratitis so unclear if results apply to other types of ocular HSV
HEDS I ⁹⁹	Adjuvant oral acyclovir vs placebo	104	Oral acyclovir did not improve time to treatment failure, but did improve BSCVA at 6 months over placebo	Only studied stromal HSV keratitis so unclear if results apply to other types of ocular HSV
HEDS II ¹⁰³	Prophylactic oral acyclovir vs placebo	703	Prophylactic oral acyclovir resulted in lower rates of recurrence	Unclear how results should be applied to superficial ocular HSV
Future Directions				
Bamdad et al., 2015 ¹¹⁹	Adjuvant CXL vs standard therapy for moderate bacterial keratitis	32	Adjuvant CXL shortened the treatment course and resulted in improved outcomes	Small sample size, investigator was partially unmasked, enrolled exclusively in Iran *
Said et al., 2014 ¹²⁰	Adjuvant CXL vs standard therapy for bacterial, fungal, <i>Acanthamoeba</i> , or mixed keratitis	40	No benefit of adjuvant CXL	Inappropriate randomization, inclusion of multiple types of keratitis and mixed keratitis, small sample size, enrolled exclusively in Egypt *
Uddaraju et al., 2015 ¹²²	Adjuvant CXL vs standard therapy for deep fungal keratitis	13	Adjuvant CXL resulted in an increased rate of perforation	Small sample size, inclusion of only severe fungal ulcers, enrolled exclusively in South India *

* results may not be generalizable