

*Drafting of the manuscript:* Smith, Oyekunle, Roche.  
*Critical revision of the manuscript for important intellectual content:* Smith, Thomas, Puscas, Roche.  
*Statistical analysis:* Oyekunle, Thomas.  
*Administrative, technical, or material support:* Smith, Puscas, Roche.  
*Supervision:* Puscas, Roche.

**Conflict of Interest Disclosures:** Mr Oyekunle reported receiving grants from the National Institutes of Health during the conduct of the study. Ms Thomas reported receiving grants from the National Institutes of Health during the conduct of the study and personal fees from AbbVie Inc outside the submitted work. No other disclosures were reported.

1. Kupferman ME, Patterson M, Mandel SJ, LiVolsi V, Weber RS. Patterns of lateral neck metastasis in papillary thyroid carcinoma. *Arch Otolaryngol Head Neck Surg.* 2004;130(7):857-860. doi:10.1001/archotol.130.7.857
2. Beal SH, Chen SL, Schneider PD, Martinez SR. An evaluation of lymph node yield and lymph node ratio in well-differentiated thyroid carcinoma. *Am Surg.* 2010;76(1):28-32. doi:10.1177/000313481007600107
3. Randolph GW, Duh QY, Heller KS, et al; American Thyroid Association Surgical Affairs Committee's Taskforce on Thyroid Cancer Nodal Surgery. The prognostic significance of nodal metastases from papillary thyroid carcinoma can be stratified based on the size and number of metastatic lymph nodes, as well as the presence of extranodal extension. *Thyroid.* 2012;22(11):1144-1152. doi:10.1089/thy.2012.0043
4. Amit M, Tam S, Boonsripitayanon M, et al. Association of lymph node density with survival of patients with papillary thyroid cancer. *JAMA Otolaryngol Head Neck Surg.* 2018;144(2):108-114. doi:10.1001/jamaoto.2017.2416
5. Schneider DF, Chen H, Sippel RS. Impact of lymph node ratio on survival in papillary thyroid cancer. *Ann Surg Oncol.* 2013;20(6):1906-1911. doi:10.1245/s10434-012-2802-8

### SARS-CoV-2 Virus Isolated From the Mastoid and Middle Ear: Implications for COVID-19 Precautions During Ear Surgery

The severe acute respiratory syndrome coronavirus 2 (SARS-CoV-2) virus and associated coronavirus disease 2019 (COVID-19) disease pandemic have rapidly spread around the world since December 2019. The high rate of droplet spread can endanger health care workers during procedures of the aerodigestive tract,<sup>1</sup> particularly affecting otolaryngologists. Although there are no human data relating to the SARS-CoV-2 virus in the middle ear, the recommendations to mitigate these risks include precautions for middle ear and mastoid surgery<sup>1,2</sup> because middle ear effusions have been shown to contain some non-SARS-CoV-2 coronaviruses.<sup>3</sup> We present confirmation of SARS-CoV-2 colonization of the middle ear and mastoid in 2 of 3 patients.

**Methods** | The Johns Hopkins Hospital research autopsy program<sup>4</sup> includes institutional review board-approved autopsy of COVID-19–positive (nasal swab, Cepheid GeneXpert SARS-CoV-2 assay) decedents, subject to safety limitations in-

cluding avoidance of powered instrumentation. Three decedents were selected, and each underwent bilateral cortical mastoidectomy and exposure of the aditus using osteotomes and curettes. Mastoid specimens included the bone and mucosa were obtained by curettage. The middle ear specimens were obtained using 3 cyto-brush swabs (Cobas polymerase chain reaction [PCR] medial dual swab, Roche). Specimens were stored in RNA media (RNAlater, Invitrogen). Nucleic acid extraction and amplification was performed per protocol. Specimens were vortexed vigorously for 30 seconds with 500 uL extracted using the BioMerieux easyMAG platform,<sup>5</sup> and specimens were eluted in 50 uL volume. Real-time reverse transcriptase-PCR was performed using the US Centers for Disease Control panel assay.<sup>5</sup>

**Results** | All 3 patients were COVID-19 positive and met SARS criteria (Table). Each sample was assayed for the N1, N2, and internal control target genes (Figure). For case 3, all samples were positive with cycle thresholds ranging from 24 to 36. Two of the 3 patients tested positive for SARS-CoV-2 virus in the mastoid or middle ear, with viral isolation from 2 of 6 mastoids and 3 of 6 middle ears. Results for case 1 were positive for the right middle ear only. Case 2 had negative results for all samples.

**Discussion** | This study confirms the presence of SARS-CoV-2 virus in the middle ear and mastoid, with significant implications for otolaryngology procedures. Similar to procedures of the nose, mouth, and airway, droplet precautions during ear surgery are warranted for patients with COVID-19 owing to risk of infection to health care personnel.<sup>1</sup> Droplet precautions (including eye protection and proper N95 level mask) are warranted for outpatient procedures involving the middle ear due to proximity to these potentially infectious spaces. Given the high asymptomatic rate of COVID-19 cases, caution is warranted for all elective ear surgery, and negative status by testing is indicated.

Limitations of this study methodology include the post-mortem interval prior to autopsy. We suspect the partial positive results of case 1 and negative results of case 2 are related to the much longer postmortem intervals. Increased intervals decrease tissue stability and affect viral stability and isolation at autopsy, and rapid autopsy protocols may provide tissue more comparable to fresh surgical biopsy.<sup>4</sup> Additional conclusions are limited, particularly regarding asymptomatic carriers. There may be many other factors and comorbidities

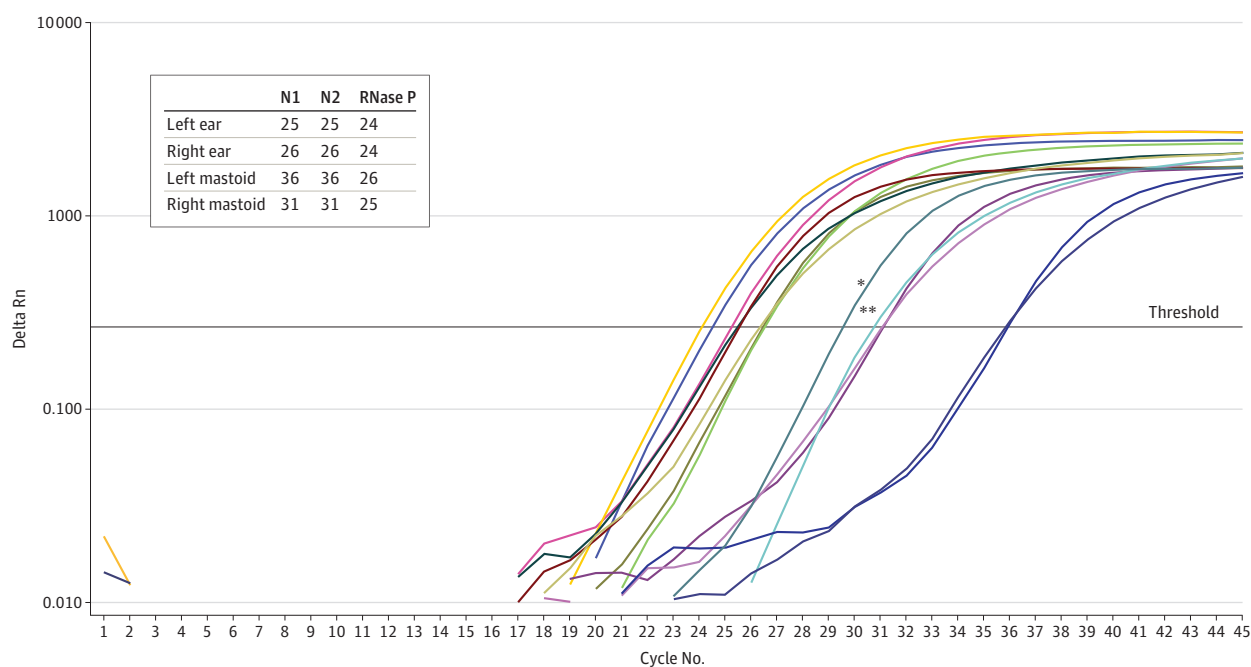
Table. Patient Demographics and Corresponding Pathology Specimen CT Values

Patient no.	Sex/age (by decade)	Post-mortem interval, h	SARS criteria	Mastoid				Middle ear											
				Left		Right		Left		Right									
				CT values	N1	N2	RP	CT values	N1	N2	RP	CT values	N1	N2	RP				
1	F/80s	48	Yes	Negative	...	...	25	Negative	...	...	26	Negative	...	...	24	Positive	...	32	26 (Effusion present)
2	F/60s	44	Yes	Negative	...	...	25	Negative	...	...	27	Negative	...	...	26	Negative	...	...	23
3	M/60s	16	Yes	Positive	36	36	26	Positive	31	31	25	Positive	25	25	24	Positive	26	26	24

Abbreviations: CT, cycle threshold; ellipses, negative gene amplification; SARS, severe acute respiratory syndrome.

←  
 Invited Commentary page 966

Figure. Amplification Plot of Patient 3



\* Indicates N1-positive control; \*\*, N2-positive control. The amplification of the N1, N2, and the internal control (RNase P) target genes is shown for specimens: left ear, right ear, left mastoid, and right mastoid. The cycle threshold values of the 3 genes for the 4 patient's specimens are shown.

that affect the colonization of the mastoid and middle ear with SARS-CoV-2, and these may differ in the living host. There may be significant differences between dying from COVID-19 vs dying with COVID-19.

We recommend the implementation of COVID-19 screening and droplet precautions for middle ear procedures when aerosol and droplet generation is reasonably expected,<sup>6</sup> as well as additional studies with in vivo samples during routine ear surgery to ascertain the incidence of viral colonization in living COVID-19-positive and COVID-19-negative patients. Identification of live virus from middle ear effusions would have implications for surgeons and staff who handle equipment such as instruments, suction tubing, and suction canisters due to current CDC biosafety recommendations. Finally, mastoid and middle ear colonization with SARS-CoV-2 does not necessarily imply current or future otologic symptomatology, and known living patients with SARS-CoV-2 ear colonization may benefit from screening for otologic manifestations.

Kaitlyn M. Frazier, MD

Jody E. Hooper, MD

Heba H. Mostafa, MBBCh, PhD, D(ABMM)

C. Matthew Stewart, MD, PhD

**Author Affiliations:** Department of Otolaryngology–Head & Neck Surgery, Johns Hopkins School of Medicine, Baltimore, Maryland (Frazier, Stewart); Department of Pathology, Johns Hopkins School of Medicine, Baltimore, Maryland (Hooper, Mostafa).

**Accepted for Publication:** June 2, 2020.

**Corresponding Author:** C. Matthew Stewart, MD, PhD, Johns Hopkins Outpatient Center, 601 N Caroline St, 6th floor, Baltimore, MD 21287 (cstewa16@jhmi.edu).

**Author Contributions:** Dr Stewart had full access to all the data in the study and takes responsibility for the integrity of the data and the accuracy of the data analysis.

**Concept and design:** All authors.

**Acquisition, analysis, or interpretation of data:** All authors.

**Drafting of the manuscript:** Mostafa, Stewart.

**Critical revision of the manuscript for important intellectual content:** All authors.

**Administrative, technical, or material support:** All authors.

**Supervision:** Mostafa, Stewart.

**Conflict of Interest Disclosures:** Dr Hooper reported grants from the National Institutes of Health during the conduct of the study. No other disclosures were reported.

**Published Online:** July 23, 2020. doi:10.1001/jamaoto.2020.1922

**Correction:** This article was corrected on September 3, 2020, to fix a missing acknowledgement of funding from the National Institutes of Health. This article was corrected online.

**Funding:** Dr Frazier's research is supported by the National Institutes of Health (NIH NIDCD 2T32DC000027).

**Role of the Funder/Sponsor:** National Institutes of Health had no role in the design and conduct of the study; collection, management, analysis, and interpretation of the data; preparation, review, or approval of the manuscript; and decision to submit the manuscript for publication.

**Additional Contributions:** We thank Michael Forman, MS, for his molecular virology laboratory and PCR expertise (uncompensated) as well as the families who granted consent for autopsy.

1. Givi B, Schiff BA, Chinn SB, et al. Safety recommendations for evaluation and surgery of the head and neck during the COVID-19 pandemic. [published online ahead of print, 2020 Mar 31]. *JAMA Otolaryngol Head Neck Surg*. 2020. doi:10.1001/jamaoto.2020.0780

2. Carron JD, Buck LS, Harbarger CF, Eby TL. A simple technique for droplet control during mastoid surgery. *JAMA Otolaryngol Head Neck Surg*. 2020:e201064. doi:10.1001/jamaoto.2020.1064

3. Seppanen EJ, Thornton RB, Corscadden KJ, et al. High concentrations of middle ear antimicrobial peptides and proteins and proinflammatory cytokines are associated with detection of middle ear pathogens in children with recurrent acute otitis media. *PLoS One*. 2019;14(12):e0227080. Published online December 26, 2019. doi:10.1371/journal.pone.0227080

4. Duregon E, Schneider J, DeMarzo AM, Hooper JE. Rapid research autopsy is a stealthy but growing contributor to cancer research. *Cancer*. 2019;125(17):2915-2919. doi:10.1002/cncr.32184
5. Uhteg K, Jarrett J, Richards M, et al. Comparing the analytical performance of three SARS-CoV-2 molecular diagnostic assays. [published online ahead of print, 2020 Apr 26]. *J Clin Virol*. 2020;127:104384. doi:10.1016/j.jcv.2020.104384
6. Sharma D, Rubel KE, Ye MJ, et al. Cadaveric simulation of otologic procedures: an analysis of droplet splatter patterns during the COVID-19 pandemic. [published online ahead of print, 2020 May 19]. *Otolaryngol Head Neck Surg*. 2020;194599820930245:194599820930245. Accessed May 28, 2020. doi:10.1177/0194599820930245

### Invited Commentary

## News Flash!—SARS-CoV-2 Isolated From the Middle Ear and Mastoid

Otolaryngologists (especially otologists and/or neurotologists) around the globe have been waiting 6 months for this study.<sup>1</sup> Given the anatomic connection from the nasopharynx, site of initial infection and virus isolation of severe acute respiratory syndrome coronavirus 2 (SARS-CoV-2) to the tympanic cavity through the eustachian tube, could the virus responsible for the coronavirus disease 2019 (COVID-19) and the current global pandemic gain access to the middle ear space and mastoid cavity, and thus put health care workers at additional risk of contracting the virus?



Related article page 964

The jury is now in. Frazier and colleagues<sup>1</sup> from the Johns Hopkins Department of Otolaryngology–Head and Neck Surgery have shown, in 2 of 3 postmortem dissections described in the article, that SARS-CoV-2 can indeed access the middle ear and mastoid. Of those 2 patients with COVID-19, SARS-CoV-2 was identified in 5 of 8 middle ear spaces and mastoid cavities. The postmortem examination in the 1 patient in whom the virus was not isolated was performed 44 hours after death, and the delay may have contributed to the negative result (or the virus may access some but not all middle ears in infected patients).

We have known for many years that viruses, including other coronaviruses, have been isolated from the middle ear space in children with acute otitis media<sup>2</sup> and in children undergoing tympanostomy tube placement for chronic otitis media with effusion<sup>3</sup>; but until now, it was unclear if SARS-CoV-2 reached the middle ear space and whether it could be isolated from the middle ear. Frazier et al<sup>1</sup> used reverse transcriptase-polymerase chain reaction (per Centers for Disease Control [CDC] guidelines<sup>4</sup>) on bone and mucosal samples dissected from the middle ear and mastoid (using osteotomes and curettes and cytobrush swabs to obtain middle ear samples) in 3 patients (1 woman in her 80s and 1 man and 1 woman in their 60s), who succumbed to COVID-19, 48, 16, and 44 hours after death.

Although no report has documented SARS-CoV-2 infection as a result of a middle ear or mastoid procedure in a health care worker, mastoidectomy clearly generates aerosols and exposes health care workers.<sup>5</sup> With sound methodology in the current report, the study implications are clear: otolaryngologists and otologists/neurotologists are at risk for contracting SARS-CoV-2 with middle ear and mastoid procedures and should don and doff personal protective equipment (PPE) per

recommended guidelines, both in the ambulatory setting and in the operating room.<sup>6–8</sup>

Mitigation strategies in the operating room must adhere to local and institutional policies and should include appropriate PPE for all health care workers in the room, at least to include N95 masks and, in some institutions, powered air-purifying respirators for the surgeon operating on patients with known SARS-CoV-2 infection, as well as drapes or protective coverings/barriers to isolate the surgical field and prevent aerosols from reaching the greater room air.<sup>9</sup> For patients with unknown viral status, universal preoperative testing has been instituted in many medical centers, but use of N95 masks, in accordance with local policy, should still be used intraoperatively during procedures that expose mastoid air cells or middle ear mucosa.

As ambulatory clinics reopen and patient care visits ramp up, practitioners in the office setting must also acknowledge the results of this study. Patient prescreening a day or 2 before the office visit, in-office screening the day of the visit, reducing the waiting room population to ensure proper social distancing, and patient isolation all can mitigate viral spread. Although further work is necessary to understand the risk of aerosolization of virus during otologic office procedures, nevertheless, suctioning the middle ear through a tympanic membrane perforation, intratympanic injections, and mastoid cavity debridement (especially if the cavity is exposed to the eustachian tube) may carry the risk of aerosolization and transmission of SARS-CoV-2; appropriate PPE, including eye protection, is indicated for these in-office procedures. Updated guidelines for otologic and neurotologic procedures, both in the operating room and in the ambulatory setting, proposed and agreed on by the American Neurotology Society, the American Otological Society, and the American Academy of Otolaryngology–Head and Neck Surgery will soon be published.

The COVID-19 pandemic has brought the world to its knees; according to the CDC in its weekly surveillance summary for the week ending June 6, 2020, across the United States “levels of influenza-like illness (ILI) and COVID-19-like illness (CLI) continue to decline or remain stable at low levels. The percentage of specimens testing positive for SARS-CoV-2 increased slightly from the prior week. Mortality attributed to COVID-19 also decreased compared to last week but remains elevated above baseline and may increase as additional death certificates are processed.”<sup>10</sup>[p1] Clearly hot spots of infection remain. Despite the overall decline or stability in infections, hospitalizations, and death rates across the country, the public, patients, and health care workers must continue to be vigilant in protecting each other and mitigating risk of viral transmission. By isolating SARS-CoV-2 from the middle ear and mastoid in postmortem ears and mastoid cavities in patients succumbing to COVID-19, the study by Frazier et al<sup>1</sup> offers proof of principle of the virus’ ability to access the middle ear and/or mastoid, documents another potential route of SARS-CoV-2 transmission, and addresses the implications for protection of health care workers caring for patients with ear disease.

**Bradley W. Kesser, MD**

**Author Affiliation:** University of Virginia Department of Otolaryngology–Head and Neck Surgery, Charlottesville.

**Corresponding author:** Bradley W. Kesser, MD, University of Virginia Department of Otolaryngology–Head and Neck Surgery, Charlottesville, VA 22903 (bwk2n@hscmail.mcc.virginia.edu).

**Published Online:** July 23, 2020. doi:10.1001/jamaoto.2020.2067

**Conflict of Interest Disclosures:** None reported.

1. Frazier KM, Hooper JE, Mostafa HH, Stewart CM. SARS-CoV-2 virus isolated from the mastoid and middle ear: implications for COVID-19 precautions during ear surgery. *JAMA Otolaryngol Head Neck Surg*. Published online July 23, 2020. doi:10.1001/jamaoto.2020.1922
2. Bulut Y, Güven M, Otlu B, et al. Acute otitis media and respiratory viruses. *Eur J Pediatr*. 2007;166(3):223-228. doi:10.1007/s00431-006-0233-x
3. Pitkäranta A, Jero J, Arruda E, Virolainen A, Hayden FG. Polymerase chain reaction-based detection of rhinovirus, respiratory syncytial virus, and coronavirus in otitis media with effusion. *J Pediatr*. 1998;133(3):390-394. doi:10.1016/S0022-3476(98)70276-8
4. CDC. Real-Time RT-PCR Panel for Detection 2019–Novel Coronavirus Centers for Disease Control. Centers for Disease Control. [https://www.who.int/docs/default-source/coronavirus/uscdrct-pcr-panel-for-detection-instructions.pdf?sfvrsn=3aa07934\\_2](https://www.who.int/docs/default-source/coronavirus/uscdrct-pcr-panel-for-detection-instructions.pdf?sfvrsn=3aa07934_2). Accessed June 14, 2020.
5. Workman AD, Welling DB, Carter BS, et al. Endonasal instrumentation and aerosolization risk in the era of COVID-19: simulation, literature review, and proposed mitigation strategies. *Int Forum Allergy Rhinol*. Published online April 3, 2020. doi:10.1002/alar.22577
6. CDC. Interim U.S. Guidance for Risk Assessment and Work Restrictions for Healthcare Personnel with Potential Exposure to COVID-19. <https://www.cdc.gov/coronavirus/2019-ncov/hcp/guidance-risk-assesment-hcp.html>. Accessed June 14, 2020.
7. Lammers MJW, Lea J, Westerberg BD. Guidance for otolaryngology health care workers performing aerosol generating medical procedures during the COVID-19 pandemic. *J Otolaryngol Head Neck Surg*. 2020;49(1):36. doi:10.1186/s40463-020-00429-2
8. Saadi RA, Bann DV, Patel VA, Goldenberg D, May J, Isildak H. A commentary on safety precautions for otologic surgery during the COVID-19 pandemic. *Otolaryngol Head Neck Surg*. 2020;162(6):797-799. doi:10.1177/0194599820919741
9. Chen JX, Workman AD, Chari DA, et al. Demonstration and mitigation of aerosol and particle dispersion during mastoidectomy relevant to the COVID-19 era. *Otol Neurotol*. 2020. doi:10.1097/MAO.0000000000002765
10. CDC. COVIDView: A Weekly Surveillance Summary of U.S. COVID-19 Activity. <https://www.cdc.gov/coronavirus/2019-ncov/covid-data/covidview/index.html>. Accessed June 14, 2020.

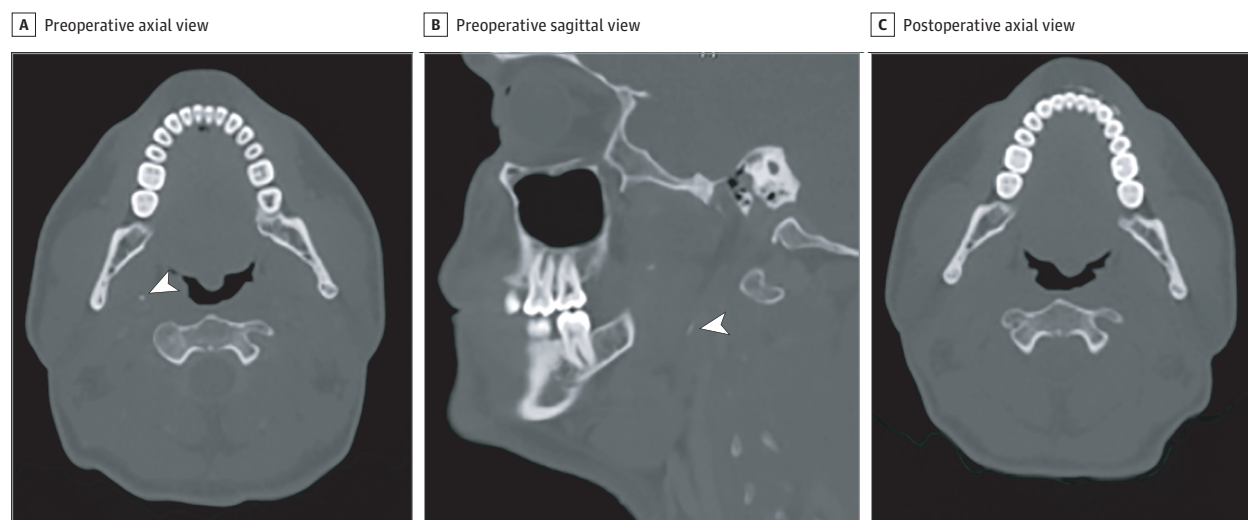
## OBSERVATION

### A Curious Case of Persistent Throat Pain—Bone Fragment in the Parapharyngeal Space

Stylalgia secondary to an elongated styloid, or the mineralization of the stylomandibular and stylohyoid ligaments, has been described in the setting of Eagle syndrome, and as a post-tonsillectomy sequela.<sup>1</sup> The incidence of an elongated styloid ranges from 4% to 18%, with most patients being asymptomatic.<sup>2,3</sup> Symptoms include odynophagia, dysphagia, pain with head turning, otalgia, facial pain, foreign body sensation, and trismus.<sup>1,2</sup> We present a case of suspected Eagle syndrome, although further workup revealed an alternate cause, which was relieved following surgical treatment.

**Report of a Case |** A healthy man in his 20s, with a history of tonsillectomy for recurrent tonsillitis, presented to clinic with a 3-month history of persistent, severe, right-sided, throbbing throat pain and dysphagia. He was treated by an outside physician with multiple courses of antibiotics and steroids, with marginal improvement. There were no overt findings on physical examination. Initial computed tomographic (CT) scan of the neck showed a calcification in the right parapharyngeal space (PPS) (Figure 1A). The patient subsequently underwent magnetic resonance angiography of the neck, which was unremarkable. The decision was made to explore the right peritonsillar and PPS intraorally. There were no intraoperative findings and the patient continued to experience discomfort. Given his persistent severe symptoms and radiologic findings, the decision was made for a transcervical exploration of the right PPS. Intraoperatively, the stylomandibular ligament was neither visualized, nor palpable. In the area of the radiologic calcification, a 7-mm bony mass was located along the course of the expected stylomandibular ligament above the digastric tendon (Figure 2). Final pathologic analysis of the specimen was

**Figure 1. Computed Tomographic Images of the Neck Examining the Right Parapharyngeal Space**



Preoperative axial (A) and sagittal (B) views (arrowheads indicate bony mass). C, Postoperative image.